



Authorship: Helena Ferreira DVM FRCPath DipACVP (Clinical Pathology) MRCVS
Axiom Veterinary Laboratories, UK

BRAF testing in urine to aid the diagnosis of transitional/urothelial cell carcinoma in dogs

Transitional cell carcinoma (TCC)/urothelial carcinoma (UC) is the most common cancer of the canine urinary tract and it affects the kidneys, bladder (especially the trigone area) and urethra of male and female dogs and also the prostate in males. TCC/UC is generally a disease of mid-to-late life.¹

Diagnosis of TCC/UC is often challenging since the clinical signs (e.g. stranguria, pollakiuria, haematuria, recurrent urinary bacterial infections) are shared with other much more common genitourinary tract disorders, including cystitis, urolithiasis and prostatitis. In most cases, dogs present with these non-specific clinical signs and are initially treated based on the assumption that there is a non-malignant cause, using repeated cycles of antibiotic administration and anti-inflammatory drugs over several months. This approach may provide temporary relief of the non-specific symptoms, but the underlying cancer is still enlarging, potentially invading across the bladder wall into the underlying muscle and forming metastases. When repeated treatments fail to fully resolve the non-specific symptoms, the dog is then evaluated for the presence of a TCC/UC, usually via cytology (e.g. urine sediment, samples obtained by traumatic catheterisation, prostatic wash and/or fine needle aspirates), abdominal ultrasound and/or cystoscopy. Histopathological evaluation of a tumour biopsy may then be required to confirm the diagnosis and assess muscular invasion.¹ At the time of diagnosis over 90% of TCC/UC cases are intermediate to high-grade invasive tumours and approximately 20% of cases have already spread to other sites.

Prognosis by then is guarded or poor. Regardless of the **treatment** options used (e.g. chemotherapy, cyclooxygenase inhibitors, radiotherapy and surgery), median survival time of treated dogs with TCC/UC is approximately 7-9 months.²

Detection of a TCC/UC earlier in the course of disease would allow appropriate intervention sooner and this would be expected to improve quality of life and prolong survival.

BRAF mutation detection assay

The canine *BRAF* gene is located on dog chromosome 16. In a normal cell, the nucleotide located at position 1784 of exon 15 of the canine *BRAF* gene is a "T" ("wild type"). In 85% of TCC/UC cases, this nucleotide has undergone a nonsynonymous change to an "A" ("mutant"), and this single mutation causes an amino acid alteration (valine to glutamic acid) in the *BRAF* protein.³⁻⁵ The mutation, referred to a canine *BRAF*^{V595E}, is the homologue of the human *BRAF*^{V600E} mutation that has been widely reported in several human cancers.⁶ The result of this mutation is a mutated protein with increased kinase activity that signals the cells to proliferate, leading to the development of a malignant tumour.

The *BRAF* assay is a non-invasive test which **identifies and quantifies** the wild-type (healthy) and mutated (neoplastic) *BRAF* alleles recovered from cells exfoliated into the urine using digital droplet PCR (ddPCR). If the *BRAF* mutation is detected, the number of *BRAF* mutant and *BRAF* wild type alleles recovered from a urine sample is used to determine the proportion of mutant alleles (**fractional abundance**).⁷ As the *BRAF* mutation is generally heterozygous, the number of cells recovered with the mutation is typically double the fractional abundance.



In samples where the *BRAF* mutation is not detected, the number of wild type alleles is used to determine the limit of detection, also referred to as the **detection threshold**, which is the level of detection that, if present, the *BRAF* mutation would have been detected in that particular sample.

Overall **sensitivity** of this test to detect a canine TCC/UC in a free-catch urine specimen is 85% and specificity is over 99%.⁷

A *BRAF* mutation **DETECTED** result indicates the presence of *BRAF* mutation load being shed into the urine, but it **does not indicate the location of the TCC/UC**. Imaging will help locate the potential source of the mutant cells and may also contribute to decisions regarding the most appropriate clinical management. Some **other canine cancers** (e.g. pulmonary carcinoma, oral SCC, melanoma, melanocytoma, glioma and peripheral nerve sheath tumour) present with the same *BRAF* mutation at low frequency³, but these have not yet been reported in urine specimens of such patients.

Unlike less discriminatory tests for canine TCC/UC (e.g. bladder tumour antigen test urine dipstick test, Sanger sequencing, qPCR approaches), the *BRAF* mutation detection assay is **not affected by the presence of blood, protein, glucose or bacteria in the urine**.⁷

Screening of high-risk breeds

Some dog breeds have a higher than average incidence of TCC/UC and these include American Eskimo dog, Australian cattle dog, Australian shepherd, beagle, bichon frise, border collie, Russell terrier, Parson Russell terrier, lhasa apso, rat terrier, Scottish terrier, Shetland sheepdog, West Highland white terrier and wire fox terrier. As the *BRAF* test was designed to identify cells carrying the *BRAF* mutation at a **forensic level of detection** (it can detect as few as 10 mutant cells in a urine sample), it can be used as a screening test to identify TCC/UC cases at preclinical stages of the disease.⁷

Monitoring

Once a dog has had the *BRAF* gene mutation detected in a urine specimen and shown to have a TCC/UC, repeat analysis may be used over time to monitor changing levels of the mutation load (fractional abundance) in free-catch urine during treatment. Preliminary unpublished data indicate that large changes in the *BRAF* mutational level in the urine over time may be used as an indicator of changes in tumour size and proliferation, and further research data are pending (Breen, M, Veterinary Cancer Society, Houston, TX, Sept. 2019).

BRAF analysis

In cases of suspected transitional/urothelial cell carcinoma (T/UCC), the *BRAF* variant V595E assay can provide a non-invasive diagnosis from a free-catch urine sample. It is not affected by the presence of blood or bacteria in the sample.

This assay detects tumour cells which carry a specific mutation in the canine *BRAF* gene. This mutation is present in approximately 80% of all canine T/UCCs, and also in prostatic carcinoma cases. It has not been detected in urine from dogs with numerous other forms of cancer, with non-malignant bladder inflammation, or with polyps.

Overall, sensitivity and specificity values of the *BRAF* test in urine DNA are approximately 85% and over 99%, respectively, for the diagnosis of T/UCC and prostatic carcinoma.

Only a positive result is conclusive.



Possible causes of negative results:

- The transitional cell/prostate carcinoma is not caused by BRAF mutation.
- There are no mutated cells present in the sample.
- It is not a transitional cell/prostate carcinoma.

Sample Requirements

If urinary bladder/urethral carcinoma (transitional cell carcinoma) is suspected:

- Urinary sediment (especially early morning urine; fluid + smear)
- Aspiration cytology (smears)
- Biopsies (formalin-fixed)

If prostate carcinoma is suspected:

- Smears rich in cells or biopsies (formalin-fixed)
- 5 - 10 ml urine, formalin fixed tissue, or smears

If urinary bladder/urethral carcinoma (transitional cell carcinoma) is suspected:

- Urinary sediment (especially early morning urine; fluid + smear)
- Aspiration cytology (smears)
- Biopsies (formalin-fixed)

If prostate carcinoma is suspected:

- Smears rich in cells or biopsies (formalin-fixed)

Case Examples

Patient 1. 14-year-old, male, crossbreed dog with “suspicious” cells on cytology and a bladder mass on ultrasound. Urine cytology (Figure 2) showed neutrophilic inflammation and atypical urothelial cells.

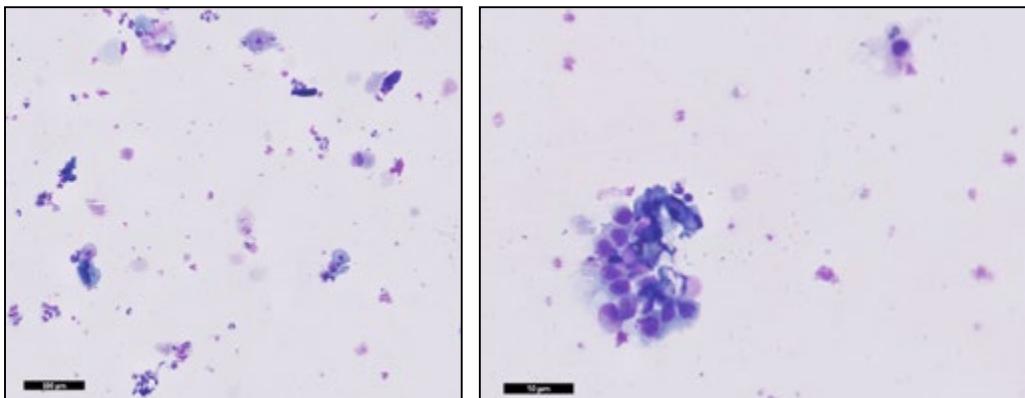
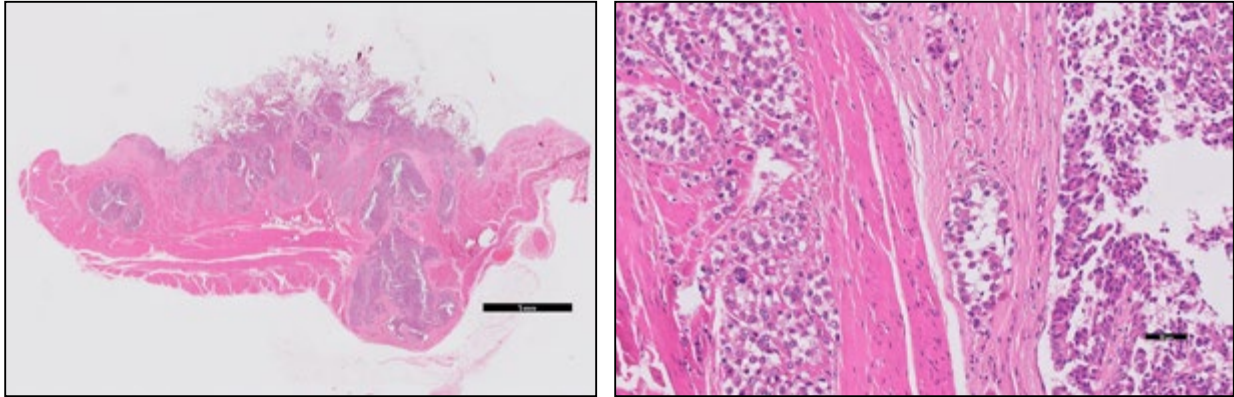


Figure 2 – 10x and 20x fields of a cytology preparation of urine from Patient 1 (Modified Wright’ stain).

The *BRAF* mutation was detected with a fractional abundance of 35% and so up to 70% (2 x 35%) of the cells recovered from the sample were consistent with being shed from a TCC/UC.



A bladder mass was collected post-mortem and histopathological examination (Figure 3) indicated the presence of a transitional cell carcinoma.



Figures 3 – 5x and 20x fields of a biopsy of a bladder mass from Patient 1 (H&E stain).

Expanding the transitional epithelium and extending deeply into the bladder wall (almost to the serosal aspect), there was a multilocular proliferating population of epithelial cells which formed loose papillary structures, sometimes more solid areas, supported by a fibrovascular stroma and with quite dense surrounding fibrosis.

Acknowledgements

Acknowledgements are due to Niki Skeldon and Alistair Cox for the cytology and histopathology reports of the case example. The histopathology microphotographs for case 2 were also provided by Alistair Cox. I thank Matthew Breen of North Carolina State University for his assistance with background information.

Clinical information is published with informed owner consent.

References

1. Fulkerson CM, Knapp DW. Management of transitional cell carcinoma of the urinary bladder in dogs: a review. *Vet J* 2015;205:217-225.
2. Meuten DJ, Meuten TLK. Tumors of the Urinary System. In: Meuten DJ, ed. *Tumors in Domestic Animals*. 5th ed. Ames, IA: Wiley Blackwell; 2017: 662-74.
3. Mochizuki H, Kennedy K, Shapiro SG, et al. BRAF Mutations in Canine Cancers. *PLoS One* 2015;10:e0129534.
4. Mochizuki H, Shapiro SG, Breen M. Detection of BRAF Mutation in Urine DNA as a Molecular Diagnostic for Canine Urothelial and Prostatic Carcinoma. *PLoS One* 2015;10:e0144170.
5. Decker B, Parker HG, Dhawan D, et al. Homologous Mutation to Human BRAF V600E Is Common in Naturally Occurring Canine Bladder Cancer--Evidence for a Relevant Model System and Urine-Based Diagnostic Test. *Mol Cancer Res* 2015;13:993-1002.
6. Holderfield M, Deuker MM, McCormick F, et al. Targeting RAF kinases for cancer therapy: BRAF-mutated melanoma and beyond. *Nat Rev Cancer* 2014;14:455-467.
7. Wiley C, Wise CF, Breen M. Novel Noninvasive Diagnostics. *Vet Clin North Am Small Anim Pract* 2019;49:781-791.
8. Shapiro SG, Raghunath S, Williams C, et al. Canine urothelial carcinoma: genomically aberrant and comparatively relevant. *Chromosome Research* 2015;23:311-331.
9. Mochizuki H, Shapiro SG, Breen M. Detection of Copy Number Imbalance in Canine Urothelial Carcinoma With Droplet Digital Polymerase Chain Reaction. *Vet Pathol* 2016;53:764-772.

Finn Pathologists

Unit 3C & 3D Mayflower Way • Harleston • Norfolk • IP20 9EB

Tel: 01379 854180 • email@finnpathologists.com • www.finnpathologists.com