



Splenic sampling for histopathology

This fact sheet provides information for the submission of splenic samples for histological examination.

Gross abnormalities of the spleen are common and often result in splenectomy with splenomegaly being the most frequent submission whether that is diffuse or nodular in nature. Diffuse splenomegaly can be the result of venous congestion (as a result of thrombosis, torsion or barbiturate injection), acute systemic infection, neoplasia or erythrophagocytosis with extramedullary haematopoiesis. Nodular lesions can either be benign or malignant, with nodular hyperplasia, haematoma formation or haemangioma being examples of benign lesions presenting as splenic masses. Haemangiosarcoma, histiocytic sarcoma and lymphoma are the most common malignancies to result in nodular splenic lesions.

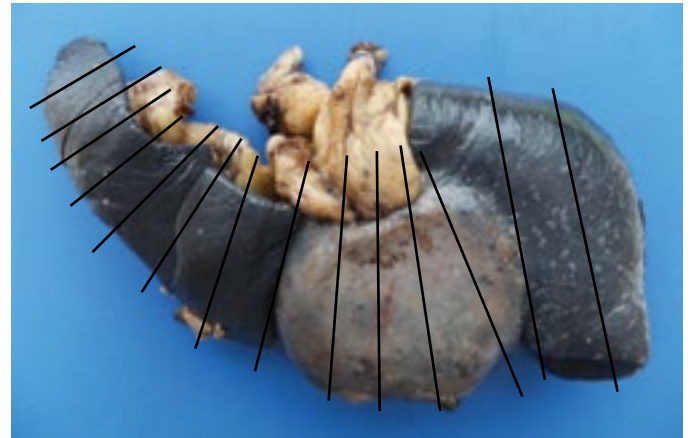
A review of canine splenic biopsies by Day and others (1995) identified neoplastic disease in 44% of submissions with benign nodular hyperplasia/haematoma in 41%. Splenic infarction with or without torsion represented 12% of submissions and inflammatory disorders 3%.

Establishing a definitive diagnosis is important to clinically manage the case. However, neoplastic lesions are often localised despite quite striking change and are prone to haemorrhage and thrombosis which can form the bulk of the mass such that the diagnostic lesion can be obscured by non-specific change such as haemorrhage, congestion, extramedullary haematopoiesis and autolysis. Therefore, appropriate sample submission is crucial in trying to establish a diagnosis.

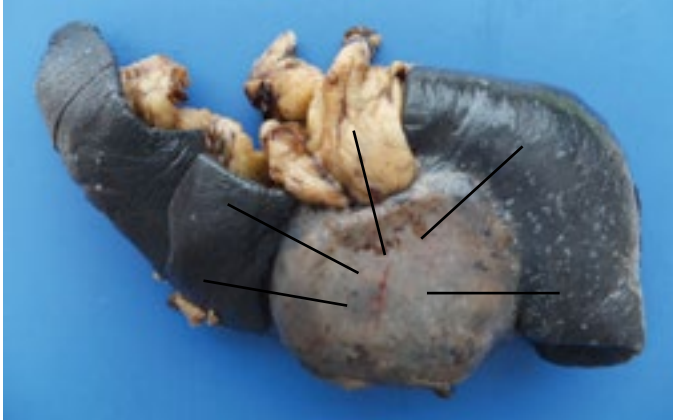Day and others found the submission of the entire spleen was more likely to yield a definitive diagnosis than multiple sections. If submitting the whole spleen we recommend that this is fixed initially at the practice before being sent to the laboratory. Once the spleen has been removed to improve fixation a series of partial incisions should be made through the capsule at approximately 1 cm intervals to allow rapid fixation

of deeper structures (see below). The spleen should then be immersed in 10% neutral buffered formalin (to reduce artefacts) at a ratio of approximately 10:1 formalin to tissue. Please refer to our other fact sheets for advice on fixation and submission of large tissue samples. We would recommend fixing whole spleens for 3-4 days before packaging for submission to the laboratory.

If it is not possible to submit the whole spleen or you are unable to do so for a variety of reasons



selective sampling of the affected portion of the spleen followed by fixation will help improve the diagnostic rate. Photographing the entire organ before sampling is useful as this can be annotated to show the sample sites and submitted at the same time as the tissue samples (either directly via email or with the accompanying laboratory submission form). The following photograph provides an outline of the suggested sampling required. This radial method captures different areas of the change and spans the periphery of the mass. These sections may need to be subdivided further to ensure rapid and adequate fixation. Submission of omental adhesions and extra-splenic omental lesions is also recommended. It is advised the remaining tissue is fixed and retained at the clinic until the final histopathology report is received in case additional material is requested.



On receipt of either the whole spleen or smaller fixed sections representative portions are processed for histological examination. If a definitive diagnosis cannot be established on initial examination additional sections would be taken for evaluation. It should though be borne in mind that a diagnosis cannot be achieved in every case despite numerous sections being taken and examined for the reasons already mentioned.

Reference:

Day, MJ, Lucke, VM and Pearson, H (1995) A review of pathological diagnoses made from 87 canine splenic biopsies. *Journal of Small Animal Practice*, 36, 426-433.

Finn Pathologists

Unit 3C & 3D Mayflower Way • Harleston • Norfolk • IP20 9EB
Tel: 01379 854180 • email@finnpathologists.com • www.finnpathologists.com